

NightLase[®]: Minimally Invasive Laser-Assisted Uvulopalatoplasty

Dr. Harvey S. Shiffman DDS¹, Dr. Matjaz Lukac²

¹Boynton Laser Dental Center, 8200 Jog Road, Boynton Beach, Florida 33742, USA

²Institut Jozef Stefan, Jamova 39, 1000 Ljubljana, Slovenia

ABSTRACT

There are a multitude of treatment options for sleep-disordered breathing (SDB), which can be classified into conservative, apparatus and surgical methods. The choice of the method used will depend on the patient's tolerance of the procedure, and most importantly, on the severity of the patient's SDB.

Laser-assisted uvulopalatoplasty (LAUP) belongs to the surgical category and is therefore commonly associated with a higher severity of treatment. However, the severity depends on the LAUP approach used. The LAUP method, which was originally introduced as a variant of the standard and relatively invasive surgical uvulopalatopharyngoplasty (UPPP) method, was modified in the early 90's to address mainly palatal flutter, which was found to be the most important factor in the mechanism of snoring. Therefore, instead of surgically shortening the palate as in UPPP, which inevitably risks impairing its function, the LAUP approach focuses on stiffening and shrinking of the palatal tissue. This is accomplished by thermally injuring the surface of the soft palate, which heals by fibrosis and/or collagen shrinkage and neocollagenesis, thus producing the desired shortening and stiffening. When performed at sub-ablative laser fluences, this type of LAUP is a "walk-in, walk out" procedure that typically does not require any anesthesia.

In this paper, clinical experience is reported on the use of an Nd:YAG/Er:YAG dental laser system to perform the LAUP procedure to reduce symptoms of sleep-disordered breathing.

Key words: Sleep-disordered breathing, SDB, snoring, laser-assisted uvulopalatoplasty, LAUP, NightLase, Nd:YAG, Er:YAG.

Article: J. LA&HA, Vol. 2018, No.1; OnlineFirst.

Received: September 28, 2018; Accepted December 6, 2018

© Laser and Health Academy. All rights reserved.

Printed in Europe. www.laserandhealth.com

I. INTRODUCTION

a) Sleep disordered breathing (SDB)

In our modern competitive society, nonrestorative sleep is acquiring an enhanced significance [1]. The international classification of sleep disorders includes 80 different diagnoses of possible causes for non-restful sleep [1, 2]. A subgroup with a comparatively high incidence rate is formed by the so-called sleep-disordered breathing (SDB) disorders [1]. These are further divided into disorders with and without obstruction of the upper airway (see Fig. 1). SDB disorders without obstruction include primary alveolar hypoventilation (Ondine's curse syndrome), secondary alveolar hypoventilation, and central sleep apnea. These clinical syndromes have neurological causes and in general resist surgical treatment.

Sleep-disordered breathing disorders with obstruction include primary snoring, upper airway resistance syndrome (UARS) and obstructive sleep apnea (OSA) [1]. Currently, these syndromes are regarded as different grades of severity of the same pathophysiological disorder.

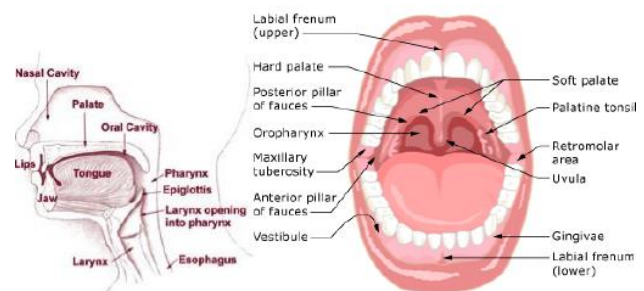


Fig. 1: Upper airway anatomy (left) and oral anatomy (right).

Snoring is caused by vibrations of soft tissue in constricted segments of the upper airway (Fig. 1). By definition, primary snoring is not accompanied by breathing impairment and entails neither disruption of sleep nor increased daytime sleepiness. In contrast to primary snoring, OSA and UARS have an adverse effect on the quality of daytime life. Cardinal symptoms of OSA are intermittent snoring (94%), daytime sleepiness (78%) and diminished intellectual performance (58%). Further symptoms are personality

changes (48%), impotence in men (48%), morning headaches (36%), and enuresis nocturna (30%) [1]. Obstructive sleep apnea is a widespread disorder affecting up to 10.9% and 6.3% of the male and female populations respectively [1].

In the case of OSA, an imbalance exists between forces dilating and occluding the pharynx during sleep. The muscle tone supporting the pharyngeal lumen is too low, and the inspiratory suction force, as well as the pressure of the surrounding tissue, which both narrow the pharynx, are too high. This disorder occurs only during sleep as a result of a physiological loss of muscle tone of the pharyngeal muscles in this state. The effects are complete cessation of breathing (apneas) or reduced breathing phases (hypopneas). If sustained long enough, both events trigger an emergency situation for the body. The body reacts with a central arousal, which disturbs physiological sleep through a release of catecholamines. The latter leads to a strain upon the cardiovascular system via an increase in the tone of the sympathetic system.

In the case of UARS, the muscle tone is still sufficient to keep a partial lumen. The respiratory resistance is thus increased to an extent requiring elevated respiratory efforts. After a certain amount of time this breathing impairment is interrupted by the same central nervous activation that is seen when apneas are terminated. The result is an increased occurrence of respiratory arousals without detectable apneas.

b) Laser-assisted uvulopalatoplasty (LAUP)

There are a multitude of treatment options for SDB, which can be classified into conservative, apparatus and surgical methods [1-13].

Conservative methods include weight reduction, optimizing sleeping hygiene, conditioning in respect to the avoidance of certain sleep positions and medicinal treatments.

Apparatus treatment options include respiratory treatment with continuous positive airway pressure (CPAP) with its various modifications, oral appliances, and electrostimulation [6, 7].

Many patients who fail medical treatment, who do not tolerate continuous positive airway pressure, or who desire a long-term solution, seek surgical management [3, 8]. Contemporary surgical treatment plans aim to identify and treat the specific site or sites of the obstruction. Surgical treatment typically targets three critical obstructive sites: the nose, oropharynx, and hypopharynx [3-5]. Uvulopalatopharyngoplasty

(UPPP) is one of the most commonly performed surgical treatments for obstructive sleep apnea [3]. Originally described by Fujita et al. in 1981 [9], UPPP involves surgical excision of the uvula and tonsils, and lateral pharyngoplasty (trimming and reorientation of the posterior and anterior tonsillar pillars). The procedure is typically performed under general anesthesia. UPPP is associated with significant postoperative pain and possible long-term complications, including nasal reflux, pharyngeal stenosis, dysphonia, and velopharyngeal insufficiency [3]. Uvulopalatal flap surgery is a less invasive procedure that widens the airway, but removes less tissue than a UPPP. Modified variants of UPPP focus on the superolateral velopharyngeal port opening without resecting functional tissues [4].

Laser-assisted uvulopalatoplasty (LAUP) is one of the less invasive variant methods used for treating snoring and obstructive sleep apnea [10]. The LAUP method was originally introduced as a variant of the standard UPPP surgical method [9], during which the uvula is partly or totally removed using laser radiation. However, because of the radical nature, complications and uncertain outcome of UPPP, a less invasive variant of the LAUP was developed originally by Ellis et al. in 1993 [15, 16]. Instead of surgically shortening the palate as in UPPP, which inevitably risks impairing its function, the less invasive LAUP approach focuses on the stiffening and shrinking of the palatal tissue.

Investigations of the mechanics of snoring show that palatal flutter is probably the most important mechanism of snoring, with the dominant parameters in the generation of flutter of the palate being its length and stiffness [14]. The “palatal stiffening” LAUP method is therefore focused on thermally injuring the surface of the soft palate, which then heals by fibrosis [15] and/or collagen shrinkage and neocollagenesis [17], thus producing the desired shortening and stiffening. When performed at sub-ablative laser fluences, this type of LAUP has been reported to be a “walk-in, walk out” procedure that typically does not require any anesthesia [17-33].

The aim of this paper is to report on 5+ years of experience in performing LAUP in a private clinic using an Nd:YAG/Er:YAG dental laser system.

II. MATERIALS AND METHODS

The laser system used is a combined Nd:YAG ($\lambda = 1064 \text{ nm}$) and Er:YAG ($\lambda = 2940 \text{ nm}$) laser system (LightWalker®, Fotona d.o.o., Slovenia). The laser system has been cleared by the FDA for laser-assisted

uvulopalatoplasty (LAUP) and intra-oral soft tissue surgery (coagulation and ablation) in addition to other indications.

Proper patient screening is performed prior to each treatment. The evaluation methods include snoring, tiredness, observed apnea, high blood pressure (STOP), body mass index, age, neck circumference, and gender (BANG) screenings [34]. The Mallampati Class is defined, and typically the patient's snoring is monitored by the SnoreLab iPhone application. A patient is treated only in case of no medical case history or symptoms of medical or disturbed sleep issues. In case of positive responses to questions, the patient is referred to a specialist for a sleep study and ENT evaluation.

The NightLase® procedure consists of first performing a minimally invasive laser-assisted uvulopalatoplasty (LAUP) using the R30 Nd:YAG laser handpiece with sub-ablative, thermally coagulative (up to ≈ 5 mm deep) laser parameters (10 W, 8 Hz, 25 ms, 8 mm spot size at the tissue). The soft palate and uvula are treated in horizontal lines in a back and forth motion with 5 full passes per line in a slow painting motion (See Fig. 2). The 1,064-nm wavelength of the Nd:YAG laser exhibits low absorption in water and is minimally absorbed by bone, but is readily absorbed by hemoglobin and pigmented soft tissues. Thereby, the Nd:YAG acts as an effective coagulator during the LAUP procedure.

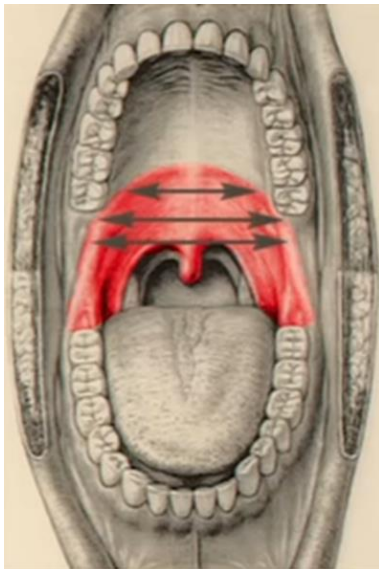

Fig. 2: Nd:YAG laser handpiece movement during the LAUP procedure.

The LAUP procedure is concluded by non-ablative superficial coagulation (0.1-0.4 mm deep) of the previously treated palatal tissue using the

Er:YAG laser's R16 handpiece (2 W, 1.5 Hz, 3.5 J/cm², Fotona SMOOTH® mode) in order to further enhance the shrinkage of collagen and neocollagenesis.

The treated tissue temperature is monitored during the procedure using a hand-held thermal camera (FLIR Systems, Inc, USA) (See Fig. 3).

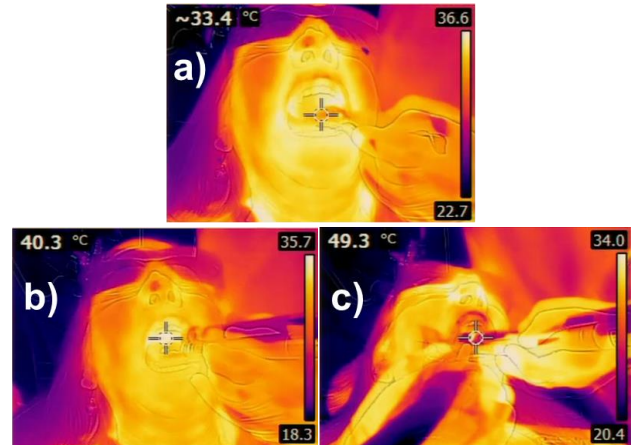


Fig. 3: Measured surface temperature of palatal tissue: a) prior to treatment; b) during Nd:YAG LAUP treatment; and c) during Er:YAG coagulation. The Nd:YAG laser wavelength has a deeper penetration within the mucous tissue than the Er:YAG laser; for this reason it is recommended that with the Nd:YAG laser, the maximal surface temperature should be lower than with the Er:YAG laser.

The complete treatment consists of three 20-minute sessions over a period of 45-60 days. No needles and no anesthesia are required, apart from the occasional use of topical anesthesia. Post-treatment pain is insignificant.

The outcome of the treatment is examined visually, and monitored with the SnoreLab iPhone application. An assessment has also been made of the patient's airway using cone beam computed tomography (CBCT) using Sirona 3D Gallileos with SICAT Air software. Follow up sleep studies are recommended for those patients who have had a diagnosis of OSA or other forms of Sleep Disordered Breathing..

III. RESULTS

The NightLase® LAUP treatment results in a visible elevation of the soft palate and uvula and tightening of the oropharyngeal tissues (Fig. 4), resulting in an improvement in the upper airway volume.

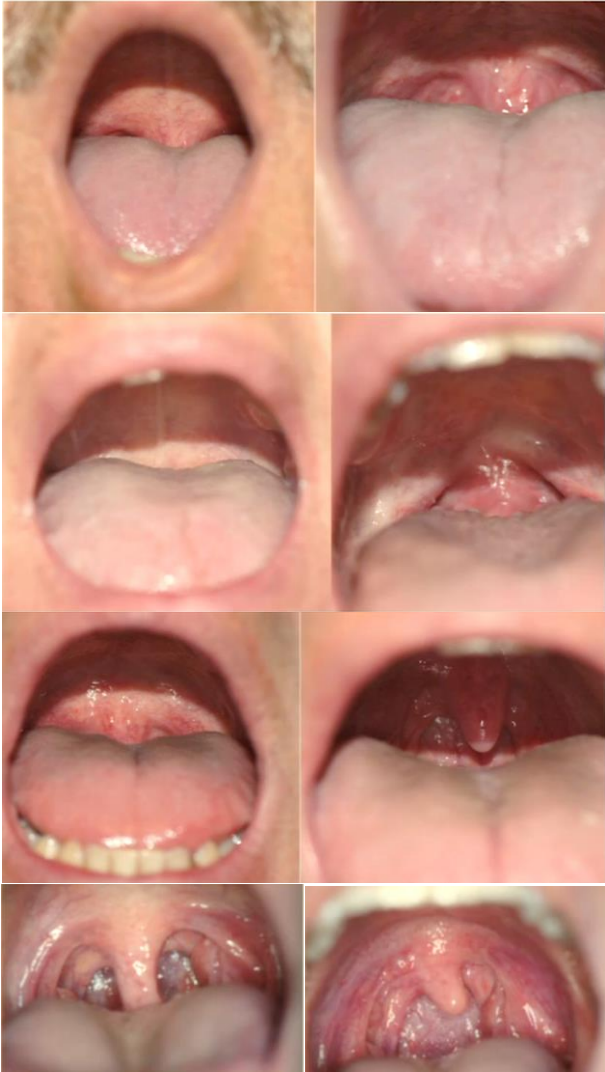

Fig. 4: Images of different patients before (left) and after NightLase® LAUP treatment.

Following the NightLase® LAUP protocol, the following muscles are observed to tighten: palatoglossus, palatopharyngeus, elevator veli palatine and tensor veli palatine. For the soft palate, palatoglossus and palatopharyngeus muscles, their fixed hard origins are the hard palate. When they are tightened up with laser energy, they move toward the hard palate. When the soft palate contracts from the laser energy, it shrinks upward and forward to the hard palate, which in turn opens up the nasopharyngeal airway and reduces snoring. The palatopharyngeus muscle, which is attached to the soft palate, also moves upward and forward with the contraction of the soft palate.

Typical reductions in snoring volume and tone at the 12-month follow-up are shown in Fig. 5. The average reduction is by $59 \pm 20\%$. When the smoking and the obese patient are excluded (See Fig. 5), the average reduction increases to $65 \pm 14\%$.

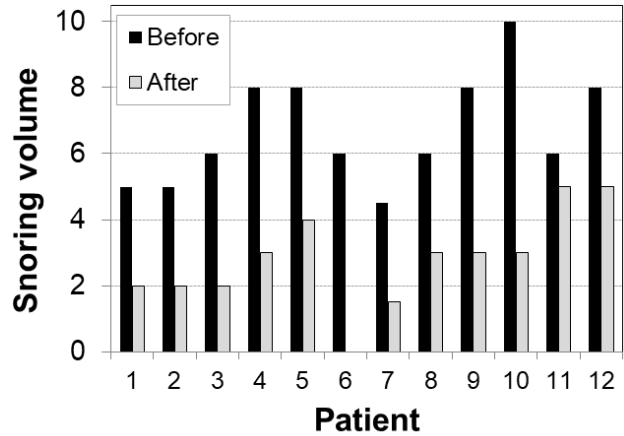


Fig. 5: The snoring volume and tone before and 12 months after the treatment. The lowest two reductions were from a smoker and an obese patient.

An example of the complete set of before and after evaluations on the same patient, consisting of three sessions performed over a period of 45 days, is shown in Figs. 6-8. The anatomical characteristics of the patient were examined prior to the treatment and Mallampati Class 3 was determined (Fig. 6 left). The snoring time as monitored by the SnoreLab application was 68%, with a snore score of 85 (Fig. 7 left). The patient's pre-treatment airway volume and minimum cross section as measured with SBCT were 18,972 mm³ and 76 mm², respectively (Fig. 8 left)

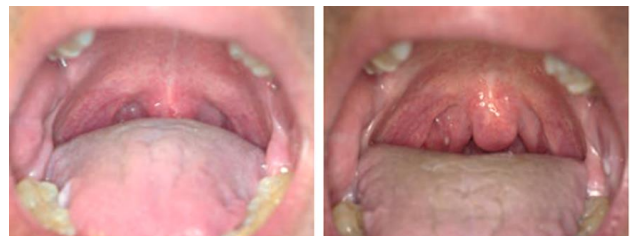

Fig. 6: Images before (left) and after (right) the treatment. The Mallampati Class was reduced from 3 to 2.

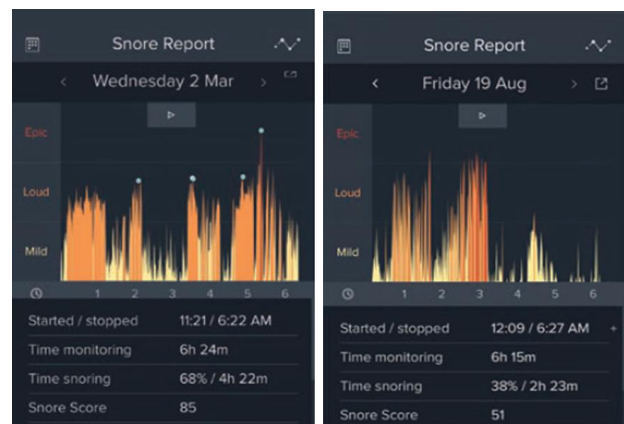


Fig. 7: SnoreLab monitoring results before (left) and after (right) the treatment. The snoring time was reduced from 68% to 38%, and the snore score was reduced from 85 to 51.




Fig. 8: Patient CBCT images taken before (left) and after (right) the treatment. The airway volume increased by 14% from 18,972 mm³ to 21,692 mm³, and the minimal cross-sectional area doubled from 76 mm² to 156 mm².

Following the NightLase® LAUP treatment, the Mallampati Class was reduced to 2 (Fig. 6 right). The snoring time was reduced from 68% to 38%, and the snore score was reduced from 85 to 51 (Fig. 7 right). The airway volume increased by 14% from 18,972 mm³ to 21,692 mm³, and the minimal cross-sectional area doubled from 76 mm² to 156 mm² (Fig. 8 right)..

IV. DISCUSSION

Extensive published research [17-33] has shown that NightLase® LAUP can reduce and attenuate snoring and provide an effective, non-invasive modality to lessen the effects of Obstructive Sleep Apnea. The procedure uses the non-ablative photothermal capabilities of the Nd:YAG and Er:YAG lasers to generate the following three components of the mechanism of action:

1. Photo-thermal interaction, during which the laser light is absorbed and the palatal tissue is heated up.
2. Thermo-mechanical interaction, during which the surface tissue starts to shrink. The temperature elevation disrupts the collagen's hydrogen bonds, altering the molecular structure of the triple-helix collagen molecules [35]. This results in immediate, linear contraction of the fibers, increasing their diameter [35-38].
3. Generation of new collagen. The thermal effect on collagen occurs not just during exposure to increased temperature, but continues throughout the processes of collagen remodeling and neocollagenesis, resulting in the generation of new collagen [39-43].

V. CONCLUSIONS

The NightLase® LAUP therapy has a significant success rate in producing a positive change in sleep patterns. No pre-medication or anesthesia is needed. The heat generated by the Nd:YAG and Er:YAG lasers during the NightLase® LAUP therapy induces

collagen contraction and neocollagenesis, resulting in a tightening of the soft palate and surrounding tissues. This causes a rise of the soft palate and a tightening of the tissues of the oropharynx, resulting in an increase of the airway volume. Because the application is non-ablative, the mucosa remains intact, which reduces the possibility of complications. The treatment may be classified as conservative. Also, patient compliance is not an issue, however, patient selection is important. If the obstruction is not located in the oropharynx, the treatment will not be effective.

As with any treatment, there are potential risks with laser treatment. However, the risks are minimal and certainly less than alternative therapies if the protocol is followed correctly. The NightLase® therapy is not a permanent alteration; it lasts anywhere from 6-12 months and is easily touched up at follow up appointments.

NOTES

One of the authors (ML) is affiliated also with Fotona d.o.o., Ljubljana, Slovenia. Dr. Shiffman conducts occasional workshops for users of Fotona LightWalker laser systems.

REFERENCES

1. Hörmann K, Verse T. Surgery for Sleep-Disordered Breathing. Berlin Heidelberg: Springer-Verlag; 2005.
2. Cowie MR. Sleep apnea: State of the art. Trends Cardiovasc Med. 2017;27(4):280-289.
3. Tanna N, Smith BD, Zapanta PE, et al. Surgical management of obstructive sleep apnea. Plast Reconstr Surg.2016;137(4):1263-1272.
4. MacKay SG, Chan L. Surgical Approaches to Obstructive Sleep Apnea. Sleep Med Clin. 2016;11(3):331-341.
5. Rotenberg BW, Vicini C, Pang EB, Pang KP. Reconsidering first-line treatment for obstructive sleep apnea: a systematic review of the literature. J Otolaryngol - Head Neck Surg. 2016;45(23):1-9.
6. Pengo MF, Steier J. Emerging technology: electrical stimulation in obstructive sleep apnoea. J Thorac Dis.2015;7(12):1286-1297.
7. Steward DL, Huntley TC, Woodson BT, Surdulescu V. Palate implants for obstructive sleep apnea: multiinstitution randomized, placebo-controlled study. Otolaryngol neck Surg. 2008;139(4):506-510.
8. Venekamp RP, Hearne BJ, Chandrasekharan D, Blackshaw H, Lim J, Schilder AGM. Tonsillectomy or adenotonsillectomy versus non-surgical management for obstructive sleep-disordered breathing in children. Cochrane database Syst Rev. 2015;(10):1-54.
9. Fujita S et al (1981) Surgical correction of anatomic abnormalities in obstructive sleep apnea syndrome: uvulopalatopharyngoplasty Otolaryngol Head Neck Surg. 89(6):923-34.
10. Camacho M, Nesbitt NB, Lambert E, et al. Laser-Assisted Uvulopalatoplasty for Obstructive Sleep Apnea: A Systematic Review and Meta-Analysis. Sleep. 2017;40(3):1-8. .
11. Yaremchuk K. Palatal procedures for obstructive sleep apnea. Otolaryngol Clin NA. 2016;49(6):1383-1397.
12. Friedman M, Ibrahim H, Bass L. Clinical staging for sleep-disordered breathing. Otolaryngol Neck Surg. 2002;127(1):13-21.
13. Choi JH, Cho SH, Kim SN, Suh JD, Cho JH. Predicting Outcomes after Uvulopalatopharyngoplasty for Adult

- Obstructive Sleep Apnea: A Meta-analysis. *Otolaryngol Neck Surg.* 2016;155(6):904-913.
14. Huang L (1992) Acoustic control for men and machines, 1992. PhD Thesis, University of Cambridge.
 15. Ellis PDM et al (1993) Surgical relief of snoring due to palatal flutter: A preliminary report. *Ann R Coll Surg Engl* 75(4):286-90
 16. Ellis PDM et al (1994) Laser palatoplasty for snoring due to palatal flutter: a further report. *Ch. Otolaryngol.* 19, 350-351
 17. Unver T, Aytugan E, Ozturan O, Kiran T, Ademci E, Usumez A. Histological Effects of Er:YAG Laser Irradiation with Snoring Handpiece in the Rat Soft Palate. *Photomed Laser Surg.* 2016;34(8):321-325.
 18. Lee, C.Y.S. & Lee, C.C.Y., 2015. Evaluation of a non-ablative Er:YAG laser procedure to increase the oropharyngeal airway volume: A pilot study. *Dental, Oral and Craniofacial Research*, 1(3), pp.56–59.
 19. Usumez A et al (2016) Histological effects of NightLase® in the soft palate of rats. *Laser* 2016(1): 28-30
 20. Algaba Guimera, J., 2015. Noninvasive treatment of snoring and sleep apnea with Erbium YAG laser. *Journal of the Laser and Health Academy*, 2015(1), p.S16. Presented at 5th LA&HA Symposium, Portorož, Slovenia, May 29th, 2015.
 21. Cetinkaya, E.A. et al., 2016. Er:Yag Laser Treatment of Simple Snorers in an Outpatient Setting. *ORL; Journal for oto-rhino-laryngology and its related specialties*, 78(2), pp.70–76.
 22. Dovsak, D. 2016. Snoring and NightLase, SMOOTH Mode Protocol. Presented at 6th LA&HA Symposium, Bled, Slovenia, May 20th, 2016.
 23. Dovsak, D., Gabrijeljic, J. & Vizintin, Z., 2011. NightLase™ – a New Laser treatment method for the reduction of snoring and sleep apnea – A pilot study. *Journal of the Laser and Health Academy*, 2011(1), pp.S09-S10. Presented at 1st LA&HA Symposium, Gozd Martuljek, Slovenia, May 19-22, 2011.
 24. Jovanovic, J., 2011. NightLase™ – Laser-assisted snoring and apnea reduction, 9 months of experience. *Journal of the Laser and Health Academy*, 2011, p.S11. Presented at 1st LA&HA Symposium, Gozd Martuljek, Slovenia, May 19-22, 2011.
 25. Miracki, K. & Vizintin, Z., 2013. Nonsurgical minimally invasive Er:YAG laser snoring treatment. *Journal of the Laser and Health Academy*, 2013(1), pp.36–41.
 26. Pang, J., 2016. NightLase® treatment for sleep-disordered breathing. *Journal of the Laser and Health Academy*, 2016(1), p.S05. Presented at 6th LA&HA Symposium, Bled, Slovenia, May 20th, 2016.
 27. Schiffman, H.S., 2016. Non-surgical laser sleep applications in dentistry. *LVI Visions*, 2016 (Winter), pp.27–28.
 28. Schiffman, H.S., 2017. TwinLight NightLase® protocol for snoring reduction therapy. *LA&HA magazine*, 5, pp.68–69.
 29. Simunovic, K. 2017. NightLase - A Blessing and a Challenge for the Patient and the Office Team. Presented at 7th LA&HA Symposium, Kranjska Gora, Slovenia, May 17-21, 2017.
 30. Sippus, J., 2015a. NightLase Procedure – Laser snoring and sleep apnea reduction treatment. *Journal of the Laser and Health Academy*, 2015(1), p.S06. Presented at 5th LA&HA Symposium, Portorož, Slovenia, May 29th, 2015.
 31. Sippus, J., 2015b. CASE REPORT: NightLase® Procedure – Laser snoring and sleep apnea reduction treatment. *Journal of the Laser and Health Academy*, 2015, pp.1–5.
 32. Sippus, J.H., 2016. Airway management with laser, snoring and sleep apnea reduction treatment case presentations with long term experience. *Short Communications O-01-01*. In *WFLD 2016*, Nagoya, Japan: The 15th Congress of the World Federation for Laser Dentistry, 17-19 July. p. 70.
 33. Svahnström, K., 2013. Er:YAG Laser Treatment of Sleep-Disordered Breathing. *Journal of the Laser and Health Academy*, 2013(2), pp.13–16.
 34. Chung F et al (2013) Predictive performance of the STOP-Bang score for identifying obstructive sleep apnea in obese patients. *Obes Surg.* 23(12):2050-7.
 35. Arnoczky SP, Aksan A (2000) Thermal modification of connective tissues: Basic science considerations and clinical implications. *J Am Acad Orthop Surg.* 8:305–13
 36. Vangsnæs CTJ, Mitchell WIII, Nimni M, Erlich M, Saadat V, Schmotzer H. Collagen Shortening: An Experimental Approach With Heat. *Clin Orthop Relat Res.* 1997;337:267–71.
 37. Kirsch KM, Zelickson BD, Zachary CB, Tope WD. Ultrastructure of collagen thermally denatured by microsecond domain pulsed carbon dioxide laser. *Arch Dermatol.* 1998;134:1255–9.
 38. Hayashi K, Thabit G, Massa KL, Bogdanske JJ, Cooley a J, Orwin JF, et al. The effect of thermal heating on the length and histologic properties of the glenohumeral joint capsule. *Am J Sports Med.* 1997;25(1):107–12.
 39. Sun Y, Chen W-L, Lin S-J, Jee S-H, Chen Y-F, Lin L-C, et al. Investigating mechanisms of collagen thermal denaturation by high resolution second-harmonic generation imaging. *Biophys J.* 2006;91(7):2620–5.
 40. Dams SD, De Liefde-van Beest M, Nuijs AM, Oomens CWJ, Baaijens FPT. Pulsed heat shocks enhance procollagen type I and procollagen type III expression in human dermal fibroblasts. *Ski Res Technol.* 2010 Aug;16(3):354–64.
 41. Hantash BM, Ubeid AA, Chang H, Kafi R, Renton B. Bipolar fractional radiofrequency treatment induces neocollagenesis and neocollagenesis. *Lasers Surg Med.* 2009 Jan;41:1–9.
 42. Hayashi K, Thabit GI, Vailas AC, Bogdanske JJ, Cooley AJ, Markel MD. Effect of Nonablative Laser Energy on the Joint Capsule: An In Vivo Rabbit Study Using a Holmium:YAG Laser. *Lasers Surg Med.* 1997;20:164–71.
 43. Lee M-WC. Combination 532-nm and 1064-nm lasers for noninvasive skin rejuvenation and toning. *Arch Dermatol.* 2003 Oct;139(10):1265–76.

The intent of this Laser and Health Academy publication is to facilitate an exchange of information on the views, research results, and clinical experiences within the medical laser community. The contents of this publication are the sole responsibility of the authors and may not in any circumstances be regarded as official product information by medical equipment manufacturers. When in doubt, please check with the manufacturers about whether a specific product or application has been approved or cleared to be marketed and sold in your country.